

Management of Graves' Disease during Pregnancy: The Key Role of Fetal Thyroid Gland Monitoring

Dominique Luton, Isabelle Le Gac, Edith Vuillard, Mireille Castanet, Jean Guibourdenche, Michèle Noel, Marie-Elisabeth Toubert, Juliane Léger, Christine Boissinot, Marie-Hélène Schlageter, Catherine Garel, Brigitte Tébeke, Jean-François Oury, Paul Czernichow, and Michel Polak

Department of Perinatology, Multidisciplinary Center for Prenatal Diagnosis (C.B., B.T., J.-F.O., D.L., E.V.), Department of Radiology (C.G.), Department of Pediatric Endocrinology and Diabetology, (J.L., P.C.), and Department of Biochemistry and Hormonology (J.G., M.N.), Robert Debré Hospital, 75019 Paris, France; Department of Nuclear Medicine, Saint Louis Hospital (M.-E.T., M.-H.S.), 75010 Paris, France; and Faculty of Medicine Paris Descartes, AP-HP, Department of Pediatric Endocrinology and Diabetology, Institut National de la Santé et de la Recherche Médicale EMI 0363 (I.L.G., M.C., M.P.), Necker-Enfants Malades Hospital, 75015 Paris, France

Background: Fetuses from mothers with Graves' disease may experience hypothyroidism or hyperthyroidism due to transplacental transfer of antithyroid drugs (ATD) or anti-TSH receptor antibodies, respectively. Little is known about the fetal consequences. Early diagnosis is essential to successful management. We investigated a new approach to the fetal diagnosis of thyroid dysfunction and validated the usefulness of fetal thyroid ultrasonograms.

Methods: Seventy-two mothers with past or present Graves' disease and their fetuses were monitored monthly from 22 wk gestation. Fetal thyroid size and Doppler signals, and fetal bone maturation were determined on ultrasonograms, and thyroid function was evaluated at birth. Thyroid function and ATD dosage were monitored in the mothers.

Results: The 31 fetuses whose mothers were anti-TSH receptor antibody negative and took no ATDs during late pregnancy had normal

test results. Of the 41 other fetuses, 30 had normal test results at 32 wk, 29 were euthyroid at birth, and one had moderate hypothyroidism on cord blood tests. In the remaining 11 fetuses, goiter was visualized by ultrasonography at 32 wk, and fetal thyroid dysfunction was diagnosed and treated; there was one death, in a late referral, and 10 good outcomes with normal or slightly altered thyroid function at birth. The sensitivity and specificity of fetal thyroid ultrasound at 32 wk for the diagnosis of clinically relevant fetal thyroid dysfunction were 92 and 100%, respectively.

Conclusion: In pregnant women with past or current Graves' disease, ultrasonography of the fetal thyroid gland by an experienced ultrasonographer is an excellent diagnostic tool. This tool in conjunction with close teamwork among internists, endocrinologists, obstetricians, echographers, and pediatricians can ensure normal fetal thyroid function. (*J Clin Endocrinol Metab* 90: 6093–6098, 2005)

GRAVES' DISEASE IS present in about 0.2% of pregnancies. Neonatal hyperthyroidism has been extensively studied, although clinical hyperthyroidism seems to occur in only 1% of neonates born to mothers with Graves' disease (1–5). The relative abundance of information available on neonates contrasts sharply with the paucity of data on the fetal effects of maternal Graves' disease. Evidence indicates a need for moving diagnostic efforts from the neonatal to the fetal period, to prevent fetal death or permanent neurological impairment (6–9). Fetal thyroid dysfunction precedes neonatal hyperthyroidism (2, 3, 9–11). The fetal thyroid gland starts secreting thyroid hormones at about wk 12 of development, and fetal TSH receptors become responsive to TSH and to TSH receptor antibodies around wk 20 (10). Whereas maternal T₄ usually crosses the placenta in only minimal (but crucial for fetal development) amounts, and TSH does not cross the placenta at all, maternal TSH

receptor antibodies freely cross the placenta and can cause overstimulation of the fetal thyroid gland during the second half of pregnancy (11). Because antithyroid drugs (ATDs) cross the placenta, administration of ATDs to the mother improves the fetal and neonatal prognosis (8, 9, 12–17). However, ATD administration to the mother can also jeopardize fetal development by inducing fetal hypothyroidism.

Few data on fetal abnormalities and outcomes are available to internists, endocrinologists, and obstetrician for devising guidelines on the management of pregnant women with Graves' disease (18). Published guidelines deal with both managing Graves' disease in the woman and predicting the risk of neonatal thyrotoxicosis. The objective of the present study was to assess fetal ultrasonography as a non-invasive tool for detecting fetal thyroid dysfunction, determining the appropriate treatment, and monitoring treatment effects during pregnancy in patients with active or treated Graves' disease. The pregnant women were included and monitored prospectively by a multidisciplinary hospital team.

Subjects and Methods

We prospectively included 72 pregnant women (72 fetuses) managed between 1999 and 2002 at Robert Debré Teaching Hospital (Paris, France) who were not included in our previous study (17). The inclusion criterion was past or current history of Graves' disease diagnosed by an

First Published Online August 23, 2005

Abbreviations: ATD, Antithyroid drug; FBS, fetal blood sampling; FHR, fetal heart rate; FT₃, free T₃; FT₄, free T₄; TRAK, TSH receptor antibody; WG, week gestation.

JCEM is published monthly by The Endocrine Society (<http://www.endo-society.org>), the foremost professional society serving the endocrine community.

endocrinologist based on clinical and laboratory test evidence of hyperthyroidism with goiter, Graves' ophthalmopathy, or dermopathy and at least one positive test for TSH receptor antibodies (19, 20). Patients were not selected based on thyroid function, disease activity, or history of thyroidectomy or ATD therapy. They were included as early as possible in the pregnancy, without exclusion criteria. A single-center design was chosen because all fetal sonograms were performed by the same person (E.V.) at Robert Debré Teaching Hospital.

In each woman, thyroid function tests and radioreceptor assay for TSH receptor antibodies (TRAK) were performed monthly from study inclusion to delivery. The treatment, in particular, the ATD therapy, was adjusted by the endocrinologist so that free T₄ (FT₄) was maintained at the upper limit of the normal range of pregnant women (our own data for 102 such women). Therefore, FT₄ levels did not differ significantly between the two groups of pregnant women (see below) or between women with and without a history of thyroidectomy. Once a month, starting at 22 wk gestation (WG), fetal heart rate (FHR) was recorded, and a fetal ultrasound scan was performed for measurements of thyroid gland size (diameter and circumference; Fig. 1A), determination of fetal growth parameters, and evaluation of fetal bone maturation. An EVB 525 variable focus ultrasound machine (Hitachi, Hialeah, FL) with a 3.5-MHz sector transducer was used for all fetal sonograms.

Fetal goiter was defined as a thyroid circumference equal or superior to the 95th percentile for gestational age, according to the normative data established by Ranzini *et al.* (21) and to our own unpublished normogram established by E.V. in 250 patients, which is consistent with Ranzini's curves (data not shown). When fetal goiter was found, color flow Doppler was performed as previously described with a velocity of 13 cm/sec (17, 22); a Doppler signal throughout the gland was considered suggestive of fetal hyperthyroidism, and a Doppler signal confined to the periphery of the gland was considered suggestive of fetal hypothyroidism (Fig. 1, B and C) (17, 22).

Bone maturation was evaluated on the sonogram obtained at 32 WG. Normally, the distal femoral ossification center is undetectable before 28 WG, is dot-like around 32 WG, is smaller than 3 mm before 33 WG, and is consistently visible after 35 WG. Accelerated bone maturation was defined as the presence of the distal femoral ossification center before 31 WG, and delayed bone maturation was defined as the absence of the center after 33 WG (23).

Fetal tachycardia was defined as an FHR continuously greater than 160 beats/min (24).

TSH, free T₃ (FT₃), and FT₄ were measured using a chemiluminescence immunoassay with the ACS-180SE system (Bayer Diagnostics, Westwood, CA). The values were interpreted according to gestational or postnatal age (25). TRAK were measured by RIA with second-generation antibodies (RIA-2 Dynotest TRAK human, BRAHMS Diagnostica GmbH, Berlin, Germany) (19). A positive result (TRAK⁺) was defined as an antibody titer greater than 2 U/liter. The results are reported as multiples of the upper limit of normal. TRAK assay results and ATD treatment were used to divide the mothers into two groups. The high-risk group, in which the fetuses were considered at risk for thyroid dysfunction, comprised mothers with at least one TRAK⁺ (20) and/or ATD treatment in the third trimester of pregnancy. The low-risk group was composed of mothers with consistently negative TRAK assays (TRAK⁻) and no ATD treatment, indicating a low risk for fetal thyroid dysfunction (26). The thyroid function did not differ between the two groups of mothers, indicating adequate ATD and/or T₄ treatment in those treated (see below).

In neonates with an age at birth of 36 WG or more, normal ranges for cord blood values were defined as follows: FT₄, 10.4–16.4 pmol/liter; and TSH, 2.6–11.8 mU/liter (25). Hypothyroidism was defined as an FT₄ level below the 2.5th percentile and a TSH value greater than the 97.5th percentile. Hyperthyroidism was defined as an FT₄ value greater than the 97.5th percentile and a TSH value below the 2.5th percentile. FT₃ levels in cord blood are normally very low and consequently unhelpful for diagnosing hypothyroidism, although they can assist in the diagnosis of hyperthyroidism. We therefore used only cord blood FT₄ and TSH for diagnosing fetal thyroid dysfunction.

Decisions to perform fetal blood sampling (FBS) were based on the treatment of the mother, Doppler signal pattern, and TRAK positivity; maternal consent was required before the procedure. FBS was not performed when the results of other tests discriminated between hypothy-

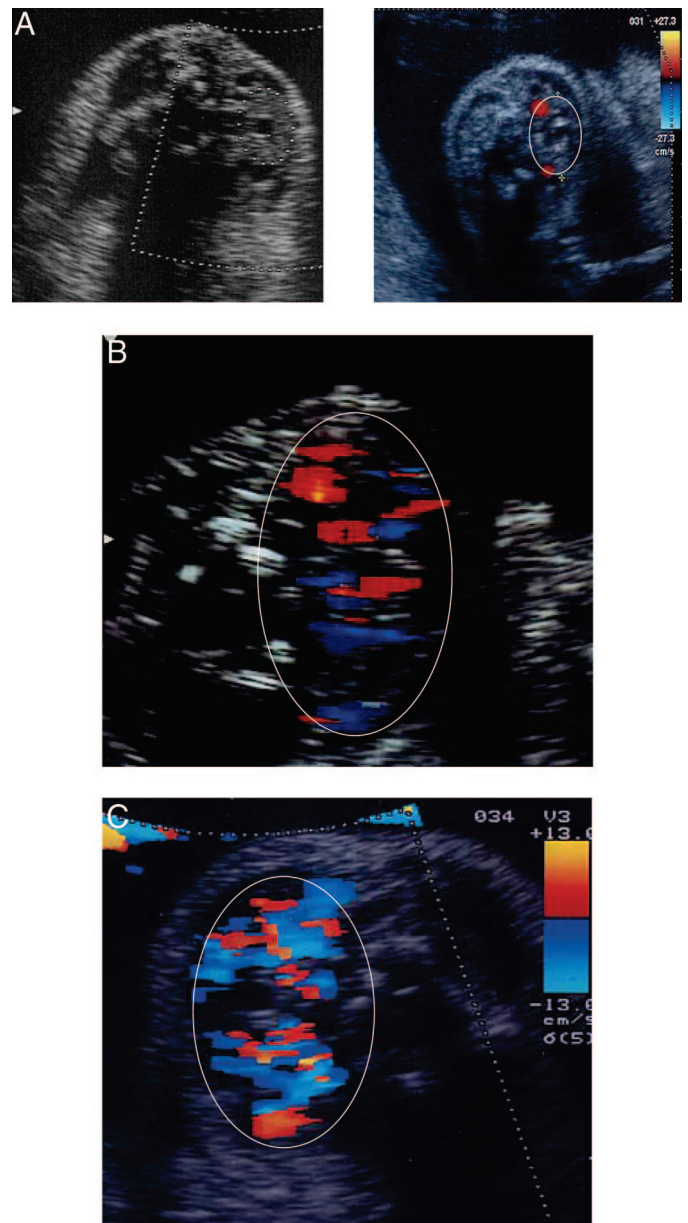


FIG. 1. Fetal thyroid and ultrasonography. A, Fetal thyroid gland with normal circumference and increased diameter. Note the central echo-free disc corresponding to the trachea and carotid arteries visualized by color Doppler. B, Fetal goiter and hypothyroidism; peripheral flash on the color Doppler. C, Fetal goiter and hyperthyroidism; central flash on the color Doppler. The measurement of fetal thyroid size has been validated and can be used in routine prenatal care. The color Doppler is still an experimental method that should be validated in more cases.

roidism and hyperthyroidism or when the pregnancy was sufficiently advanced to allow induction of labor within a reasonable period (27).

Once the type of fetal thyroid dysfunction was determined, the treatment consisted of an ATD dosage increase when the diagnosis was fetal hyperthyroidism [with maternal levothyroxine (L-T₄) therapy if needed] and of ATD withdrawal or dosage reduction when the diagnosis was fetal hypothyroidism, as permitted by the maternal endocrine status. When early-onset fetal hypothyroidism was diagnosed, intrauterine intraamniotic L-T₄ was administered by amniocentesis, as previously described (17). Of note, this approach has been used sparingly and should only be discussed by teams used to this type of prenatal care.

At delivery, cord blood was retrieved for thyroid function tests, the newborn was examined by a pediatric endocrinologist, and ultrasonography of the thyroid gland was performed (28).

This study was approved by the Paris-Saint Louis ethics committee for biomedical studies in humans and was conducted in compliance with French law. Written informed consent was obtained from the pregnant women.

Results

Description of the cohort of women with Graves' disease (n = 72)

The mean age in the overall population was 33 yr (range, 26–43 yr). The gestational age at inclusion was 17 WG (range, 10–28 WG). Of the 72 women, 41 were in the high-risk group, and 31 were in the low-risk group. Details are given in Table 1. Overall, 45 women received no treatment or only L-T₄, and 27 received ATD therapy (with or without L-T₄). Of the 41 high-risk women, 33 had at least one TRAK⁺ result during pregnancy, and eight received ATD therapy during the last trimester, but had consistently TRAK⁻ tests; these eight patients were treated because of recent onset or exacerbation of Graves' disease, in keeping with the widely recognized need for giving ATD therapy for 18 months and not more (20). Of the 26 women with a history of total (n = 3) or subtotal (n = 23) thyroidectomy, 9 (34%) had at least one TRAK⁺ test during pregnancy.

Fetal thyroid function and its relation to maternal thyroid function

In the low-risk group (n = 31), fetal sonograms showed no evidence of goiter. Cord blood thyroid function tests were normal at delivery in all 31 neonates. Thyroid dysfunction did not develop in any of these neonates during the first postnatal month (Fig. 2).

In the high-risk group (n = 41), 11 of the 41 fetuses had ultrasonogram evidence of goiter at 32 WG and, consequently, were evaluated for thyroid dysfunction (Fig. 2). The results showed hypothyroidism in seven fetuses and hyperthyroidism in four fetuses at 32 WG (Table 2).

Fetal hypothyroidism was usually associated with low maternal TRAK titers, high ATD dosages (≥ 150 mg/d propylthiouracil, ≥ 15 mg/d methimazole, or ≥ 100 mg/d benzylthiouracil), and/or delayed fetal bone maturation. The Doppler signal was positive throughout the fetal thyroid gland in two cases and at the periphery of the gland in four cases; it was not detected in one case and was not documented in one case. Delayed bone maturation was noted in two of these seven fetuses. Fetal blood was obtained in four

TABLE 1. Treatment during pregnancy and TRAK status in the women

	TRAK ⁺	TRAK ⁻
ATD	16	8
ATD + L-T ₄	3	0
L-T ₄	6^a	17
None	8^a	14
Total	33	39

Data are shown for 41 high risk women, 33 from the TRAK⁺ column and eight from the TRAK⁻ column treated with ATDs (in bold).

^a All but three were TRAK⁺ after 20 WG. The three remaining patients were TRAK⁺ in the first trimester and TRAK⁻ subsequently.

Ultrasonographic thyroid monitoring and thyroid function in 72 fetuses

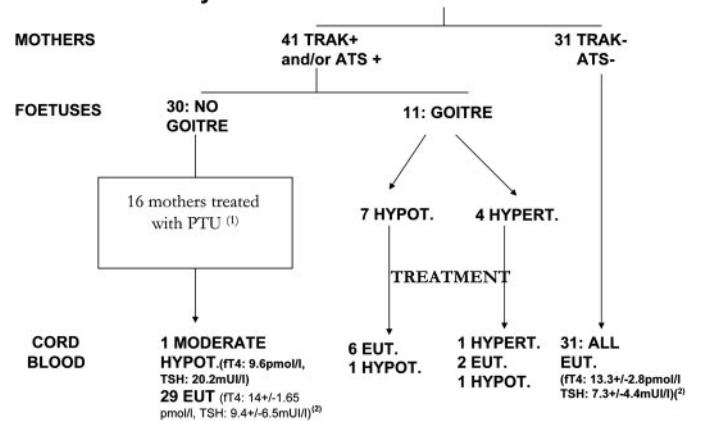


FIG. 2. Ultrasonography for fetal thyroid monitoring according to maternal status and cord blood thyroid function test results. Hypot, Hypothyroidism; Eut, euthyroidism; Hypert, hyperthyroidism. 1) In one mother, FT₄ (20.2 pmol/liter) was at the upper limit of normal with suppressed TSH (<0.05 mIU/liter) despite the high maternal dose of propylthiouracil (PTU). 2) FT₄, Mean of FT₄ in all of these newborns with 1 sd; TSH, mean TSH in all of these newborns with 1 sd.

cases for thyroid function tests, which confirmed the diagnosis of fetal hypothyroidism. The ATD dosage was reduced in all seven cases, and L-T₄ was injected into the amniotic fluid in three fetuses after confirmation of hypothyroidism by fetal blood sampling. In one case (no. 4, Table 2), FBS was not performed because the low TRAK level led us to postulate that the fetus had hypothyroidism. This prompted us to decrease the ATD dose. This appeared subsequently to be correct, because a decrease in thyroid size occurred 2 wk later. Indeed, after treatment, sonograms performed at 2-wk intervals consistently showed a decrease in the size of the thyroid gland; in two cases, the gland returned to normal size.

Thyroid function did not differ between the low-risk and high-risk groups of mothers. In the low-risk group, mean \pm SD FT₄ and FT₃ levels during the third trimester were, respectively, 12.4 ± 1.3 and 4.1 ± 0.3 pmol/liter, not different from those in the high-risk group (13.9 ± 2.5 and 4.8 ± 1.1 pmol/liter). Even the maternal FT₄ and FT₃ levels in the three women with fetuses with the more severe hypothyroidism (Table 2) did not differ from those in the other women of the high-risk group (mean of the third trimester: case 1: FT₄, 12.2 pmol/liter; FT₃, 4.1 pmol/liter; case 5: FT₄, 11.2 pmol/liter; FT₃, 3.9 pmol/liter; case 7: FT₄, 15.3 pmol/liter; FT₃, 5.2 pmol/liter; Table 2). However, at the time of FBS and ultrasonography, FT₄ and FT₃ in those three women were: case 1: FT₄, 8.6 pmol/liter; FT₃, 3.2 pmol/liter; case 5: FT₄, 9.7 pmol/liter; FT₃, 3.9 pmol/liter; and case 7: FT₄, 16.1 pmol/liter; FT₃, 5 pmol/liter (Table 2).

At birth, cord blood tests showed normal FT₄ levels in six babies and a borderline low FT₄ in one (Table 2). Within the first postnatal week, hyperthyroidism requiring ATD therapy developed in three of these seven neonates (Table 2, upper part). The mothers of these seven fetuses had normal thyroid function.

Fetal hyperthyroidism (n = 4) was usually associated with high maternal TRAK titers and/or accelerated fetal bone

TABLE 2. Fetuses at 32 WG: seven with hypothyroidism (cases 1–7) and four with hyperthyroidism (cases 8–11)

Case no.	32 WG								Birth		
	TRAK ULN ^a	Treatment dose (mg/d)	Doppler ^b	Fetal blood sampling ^c		IAT ₄	FHR	Bone ^d	Cord blood ^e		Neonatal hyperthyroidism
				FT ₄ (pmol/liter)	TSH (mIU/liter)				FT ₄ (pmol/liter)	TSH (mIU/liter)	
1	0	PTU 300	Periph	5.2	449	Yes	Normal	Normal	13.9	10.8	No
2	0	PTU 100	Periph	7	56	No	Normal	Normal	12	13.5	No
3	20	PTU 300	Periph				Normal	Delayed	9.7	5	Yes
4	1.8	PTU 100	Total				Normal	Normal	12.8	10.5	Yes
5	4	PTU 300	Total	3.9	483	Yes	Normal	Normal	13.9	12	No
6	1.8	PTU 50	Periph				Normal	Normal	12	2.5	No
7	8	NCZ 30	No	5.3	323	Yes	Normal	Delayed	16.4	2.4	Yes
8	37	PTU 200	Total				Normal	Advanced	8.4	6.6	Yes
9	325	NCZ 30	Total	51.7	<0.05		>160	Normal	19.3	<0.05	Death
10	19	PTU 250	Total				Normal	Advanced	12.9	<0.05	Yes
11	3.3	PTU 250	Total	14.8	<0.05		Normal	Normal	15.2	4.4	No

^a Number of times the upper limit of normal.

^b Periph, Peripheral signal; Total, signal throughout the thyroid gland; IAT₄, intraamniotic L-T₄ injection.

^c A value of 14 pmol/liter is the upper limit of our normal data [the fetus with FT₄ of 14.8 pmol/liter had FT₃ of 7.5 pmol/liter for an upper limit of normal of 1.9 pmol/liter (25)].

^d Bone maturation.

^e Normal ranges for cord blood values were: FT₄, 10.4–16.4 pmol/liter; and TSH, 2.6–11.8 mIU/liter (25).

maturation. The Doppler signal was positive throughout the fetal thyroid gland in all four cases. Advanced bone maturation was noted in two fetuses. In two cases, after a multidisciplinary evaluation, fetal blood tests were performed and confirmed the diagnosis, showing a very high T₄ value (51.7 pmol/liter) and a minimally elevated value (14.8 pmol/liter), but a high T₃ level (7.5 pmol/liter) in this case and both cases with low TSH levels (<0.05 mIU/liter; Table 2). The ATD dosage was increased in all four mothers. The size of the fetal thyroid gland decreased within the next 2 wk; it returned to normal in one fetus. However, one fetus died *in utero* at 35.5 WG from congestive heart failure with cardiomyopathy. This was a late-referred case with very high TRAK values and a preexisting fetal goiter, as shown by a positive central Doppler flash at 22 WG. ATD therapy was increased up to 60 mg methimazole/d to no effect. FBS confirmed the diagnosis of severe hyperthyroidism, and the fetal blood TRAK titer was massively elevated (325 ULN). Of the three surviving fetuses, one had normal cord blood thyroid function tests at birth with no subsequent hyperthyroidism, one had normal FT₄ with low TSH at birth, and one had cord blood values indicating mild low FT₄ with normal TSH, which resolved spontaneously without treatment after clearance of the maternal ATD (Table 2). Within the first postnatal week, hyperthyroidism requiring ATD therapy developed in two of these three neonates (Table 2, lower part). Of the four mothers, two had hyperthyroidism and two had normal thyroid function.

The remaining 30 fetuses in the high-risk group had no goiter and consequently were not considered at risk for thyroid dysfunction (Fig. 2). All had normal thyroid values in cord blood at delivery, except one neonate who had moderate hypothyroidism (FT₄, 9.6 pmol/liter; TSH, 20.6 mIU/liter) that resolved spontaneously without treatment. Retrospectively, this case could have been detected, because a peripheral color Doppler signal was noted at 38 WG, when thyroid gland size parameters were at the upper limit of normal.

Based on the results of thyroid cord blood testing at de-

livery and the therapeutic interventions in the treated fetuses, the sensitivity and specificity of fetal thyroid ultrasound at 32 WG in screening for clinically relevant (leading to therapeutic action) fetal thyroid dysfunction were 92% and 100%, respectively (Table 3). This clearly indicates a major role for fetal thyroid ultrasonography in diagnosing fetal thyroid dysfunction.

Discussion

Fetuses and neonates born to mothers with Graves' disease are at risk for thyroid dysfunction if the mother tests positive for TRAK and/or receives ATD therapy during pregnancy. The first major finding from our study is that fetal function was normal before and after birth in the offspring of the 31 low-risk women. These women had TRAK⁻ tests throughout pregnancy and took no ATDs during the last trimester of pregnancy, indicating resolution of Graves' disease; some of these women were taking L-T₄, usually because of a history of thyroidectomy. In contradiction to the European Thyroid Association guidelines, this result highlights the importance of TRAK determination in pregnant women with Graves' disease (18) and shows that no special care is required when TRAK tests are negative. Furthermore, nine (34%) of the 26 patients with a history of

TABLE 3. Fetal thyroid ultrasonogram in screening for fetal thyroid dysfunction

	Fetal thyroid dysfunction	No fetal thyroid dysfunction ^a
Goiter	TP = 11	FP = 0
No goiter	FN = 1	TN = 60

Sensitivity, 92%; specificity, 100%; positive predictive value, 100%; negative predictive value, 98%. These values were calculated with our criteria at 32 WG when screening for clinically relevant (leading to therapeutic action) fetal thyroid dysfunction and are based on the values of the thyroid cord blood testing at delivery and the therapeutic interventions in the treated fetuses. FP, False positive; FN, false negative; TN, true negative; TP, true positive.

^a Measured in cord blood at delivery.

thyroidectomy were TRAK⁺, indicating that TRAK assays should be performed in this patient subgroup, at least at the beginning of pregnancy. This later point is in line with European Thyroid Association recommendations (18).

Propylthiouracil was the most widely used ATD among the women who took ATD therapy during pregnancy. This drug is currently preferred over methimazole based on its lower teratogenic potential, even if its limited transplacental passage has been shown to be similar to that of methimazole in an *in vitro* assay using the isolated perfused placenta lobule (29). Indeed, methimazole given during organogenesis has been reported to cause aplasia cutis and tracheoesophageal fistula as well as a characteristic embryopathy (30, 31).

The second important finding of our study is that 11 (27%) of the 41 fetuses from high-risk mothers had goiter by fetal ultrasonography. Normograms for fetal thyroid size were published by Ranzini *et al.* in 2001 (21) and were validated in our setting in 250 euthyroid pregnant women (our own unpublished observations), thus allowing a precise diagnosis of fetal goiter. Monthly fetal thyroid ultrasonograms ensured the detection of all cases of fetal goiter and therefore of all cases of clinically significant (requiring therapeutic modifications) thyroid dysfunction with 100% specificity. Indeed, it has been reported that at birth, several offspring of mothers with Graves' disease treated with ATD had transient elevated TSH levels and no goiter (32, 33). However, no neonatal thyroid ultrasound was performed; therefore, the presence of subtle thyroid enlargement cannot be ruled out (32, 33). Moreover, this technique can be acquired by ultrasonographers, thus allowing its widespread use. Nachum *et al.* (34) recently reported data from 18 women managed over a period of 10 yr. In these patients, fetal blood sampling was extensively practiced even in the absence of fetal goiter and occasionally revealed fetal thyroid dysfunction. This discrepancy with our results can be explained by the fact that fetal sonograms were less standardized in the study by Nachum *et al.* (34). Our data establish that fetal blood sampling is unnecessary in the absence of fetal goiter. Similarly, Kilpatrick (35) stated that isolated high TRAK titers are not sufficient to recommend routine FBS. In a series of 20 women, including five with goiter in the fetus, Cohen *et al.* (36) also obtained convincing evidence that ultrasonography is an effective noninvasive screening tool for detecting fetal goiter. However, they did not assess maternal TRAK titers, so the interpretation of fetal goiter in their study is difficult.

In fetuses with goiter, the main clinical problem was to determine whether the cause was maternal treatment that was adequate to achieve normal maternal thyroid function but inadequate and excessive for the fetus and therefore responsible for fetal hypothyroidism or fetal thyroid stimulation by maternal Graves' disease IgGs responsible for fetal hyperthyroidism.

It is generally agreed that fetal FT₄ levels correlate with maternal FT₄ levels and that fetal euthyroidism can be achieved by maintaining maternal FT₄ in the upper normal to mildly thyrotoxic range during antithyroid drug treatment. This fact is underlined by the present results, because maternal FT₄ levels in the three cases with extremely severe hypothyroidism were in the normal range in case 7 and in the lower normal range in the two others (cases 1 and 5). Therefore, in these two last cases, the maternal FT₄ level may have also helped us in the diagnosis of fetal hyperthyroidism.

Nevertheless, we mainly used a combination of maternal criteria (TRAK titer and ATD use and dosage) and fetal criteria (thyroid Doppler signal, FHR, and bone maturation) to distinguish between fetal hypothyroidism and hyperthyroidism. FBS was only discussed after the patient's agreement and if there was a fetal goiter with no possibility of distinguishing hypothyroidism and hyperthyroidism using maternal and fetal criteria. Fetal hyperthyroidism was diagnosed based on high maternal TRAK titers, accelerated fetal bone maturation, and an FHR greater than 160 beats/min; this last sign was uncommon, because it occurs late in the natural history of fetal hyperthyroidism. The limited usefulness of FHR for diagnosing fetal hyperthyroidism has also been underlined by Nachum *et al.* (34). Doppler examination of the fetal thyroid gland proved useful only when the flash was confined to the periphery of the gland, a pattern suggestive of fetal hypothyroidism. The prenatal response to treatment and the results of thyroid function tests of fetal blood when obtained and of cord blood at birth indicated that our criteria were effective in differentiating hypothyroidism and hyperthyroidism in all 11 fetuses with goiter.

Fetal blood was sampled from six of the 11 fetuses with goiter, and the results consistently confirmed the suspected diagnosis. Abortion, fetal bradycardia, and infection have been reported after FBS in 1% of cases (27). Consequently, FBS should be reserved for those cases in which intraamniotic T₄ injection is considered or thyroid status is in doubt in a fetus whose mother has TRAK⁺ assays and receives ATD therapy.

Routine cord blood assays of FT₄ and TSH at delivery allowed us to validate our prenatal strategy, but did not help us to predict subsequent neonatal thyroid dysfunction, as reported previously (37). Indeed, the remaining 30 fetuses in the high-risk group had no fetal goiter, and it should be noticed that the major evidence of the absence of fetal thyroid dysfunction is based on the results from cord blood at birth. Normal thyroid function *in utero* was not definitively demonstrated, because FBS appeared unnecessary and, therefore, unethical in this group of patients.

From our data we suggest the following strategy for the care of these pregnancies, which differs from that of the European Thyroid Association. It should now be validated in other datasets, taking into account our sample size. TRAK should be assayed routinely when the fetal thyroid is functioning. For practical reasons, we believe that it can be performed at the beginning of pregnancy in women with current or past history of Graves' disease; indeed, it can be performed with other screening procedures offered to pregnant women at 12–13 WG, and a negative result will avoid unnecessary additional work-up. During pregnancy in women who are receiving ATD therapy and/or who have positive tests for TRAK, a fetal ultrasonogram should be performed monthly after 20 WG to screen for goiter and/or other evidence of fetal thyroid dysfunction. During pregnancy in a woman with negative tests for TRAK and not receiving ATD treatment, the usual ultrasonograms during pregnancy (recommended in France at 22 and 32 WG) should be performed. Of note, most fetal thyroid dysfunction (10 of 11 cases) arose in women with no history of thyroidectomy in our high-risk group, whereas only one case was observed in the offspring of the 26 women who underwent thyroidectomy. Therefore, the former group should be the target of careful prenatal follow-up.

In conclusion, our study shows that prenatal screening ultrasonography is a powerful tool for detecting fetal thyroid dysfunction in maternal Graves' disease. Ultrasonogram monitoring of fetuses from mothers with Graves' disease was extremely sensitive and specific for detecting intrauterine thyroid dysfunction and therefore allowed appropriate fetal management. In that it was a prospective and systematic study of fetal thyroid size, it is a new approach, which is not comparable to previous studies. This tool in conjunction with close teamwork among internists, endocrinologists, obstetricians, echographers, and pediatricians can ensure normal fetal thyroid function. Whether this systematic monitoring makes a difference in terms of ultimate psychomotor development of the children compared with more targeted investigations remains to be demonstrated.

Acknowledgments

We thank Dr. Madec (Institut National de la Santé et de la Recherche Médicale Unité 449, Lyon, France), for her help with assaying thyroid-stimulating Ig activity; Dr. Magnier (Pediatric Cardiology, Robert Debré Hospital, Paris, France) for her help in performing the echocardiograms; and the maternity staff, especially Mrs. Schaller and Mrs. Savary, the midwives, and the nurses.

Received December 27, 2004. Accepted August 16, 2005.

Address all correspondence and requests for reprints to: Pr. Michel Polak, Service d'Endocrinologie et Diabétologie Pédiatriques, Institut National de la Santé et de la Recherche Médicale, EMI 0363, Hôpital Necker Enfants-Malades, 149 rue de Sévres, 75015 Paris, France. E-mail: michel.polak@nck.ap-hop-paris.fr.

This work was supported by the Groupe de Recherche sur la Thyroïde, particularly Prof. Caron (Endocrinology, Toulouse, France), Prof. Orgiazzi (Endocrinology, Lyon, France), and Prof. Wemeau (Endocrinology, Lille, France). The study received support from four firms: Brahms for the TRAK assays; Serono through an educational grant (to I.L.G.); Bayer for the T₃, T₄, and TSH assays; and Merck. Part of this work was presented in abstract form at the annual meeting of the European Society for Pediatric Endocrinology, Ljubljana, Slovenia, September 2003.

References

- Polak M 1998 Hyperthyroidism in early infancy: pathogenesis, clinical features and diagnosis with a focus on neonatal hyperthyroidism. *Thyroid* 8:1171–1177
- McKenzie JM, Zakarija M 1992 Fetal and neonatal hyperthyroidism and hypothyroidism due to maternal TSH receptor antibodies. *Thyroid* 2:155–159
- Foley TP 1991 Advances in perinatal thyroidology. In: Bercu BB, Shulman DI, eds. *Maternally transferred thyroid disease in the infant: recognition and treatment*. New York: Plenum; 209–226
- Eason E, Costom B, Papageorgiou AN 1982 Hypertension in neonatal thyrotoxicosis. *J Pediatr* 100:766–768
- Neal PR, Jansen RD, Lemons JA, Mirkin LD, Schreiner RL 1985 Unusual manifestations of neonatal hyperthyroidism. *Am J Perinatol* 2:231–235
- Daneman D, Howard NJ 1980 Neonatal thyrotoxicosis: Intellectual impairment and craniosynostosis in later years. *J Pediatr* 97:257–259
- Kopelman AE 1983 Delayed cerebral development in twins with congenital hyperthyroidism. *Am J Dis Child* 137:842–845
- Cove DH, Johnston P 1985 Fetal hyperthyroidism: experience of treatment with four siblings. *Lancet* 23:430–432
- Polak M, Leger J, Luton D, Oury JF, Vuillard E, Boissinot C, Czernichow P 1997 Fetal cord blood sampling in the diagnosis and the treatment of fetal hyperthyroidism in the offspring of a euthyroid mother, producing thyroid stimulating immunoglobulins. *Ann Endocrinol (Paris)* 58:338–342
- Burrow GN, Fisher DA, Larsen PR 1994 Maternal and fetal thyroid function. *N Engl J Med* 331:1072–1078
- Zakarija M, McKenzie JM 1983 Pregnancy-associated changes in the thyroid-stimulating antibody of Grave's disease and the relationship to neonatal hyperthyroidism. *J Clin Endocrinol Metab* 57:1036–1041
- Porreco RP, Bloch CA 1990 Fetal blood sampling in the management of intrauterine thyrotoxicosis. *Obstet Gynecol* 76:509–512
- Bruinse HW, Vermeulen-Meiners C, Wit JM 1988 Fetal treatment for thyrotoxicosis in non-thyrotoxic pregnant women. *Fetal Ther* 3:152–157
- Momotani N, Noh JY, Ishikawa N, Ito K 1997 Effects of propylthiouracil and methimazole on fetal thyroid status in mothers with Graves' hyperthyroidism. *J Clin Endocrinol Metab* 82:3633–3636
- Bricaire H, Viron B, Czernichow P, Luton JP 1983 Traitements par antithyroïdiens de synthèse au cours de la grossesse. *Presse Med* 12:1057–1061
- Matsuura N, Konishi J, Fujieda K, Kasagi K, Iida Y, Hagiwara M, Fujimoto S, Fukushi M, Takasugi N 1988 TSH-receptor antibodies in mothers with Graves' disease and outcome in their offspring. *Lancet* 1:14–17
- Volumenie JL, Polak M, Guibourdenche J, Oury JF, Vuillard E, Sibony O, Royal F, Raccach-Tebeke B, Boissinot C, Madec AM, Orgiazzi J, Toubert ME, Leger J, Blot P, Luton D 2000 Management of fetal thyroid goitres: a report of 11 cases in a single perinatal unit. *Prenat Diagn* 20:799–806
- Laurberg P, Nygaard B, Glinoeer D, Grussendorf M, Orgiazzi J 1998 Guidelines for TSH-receptors antibody measurements in pregnancy: results of an evidence-based symposium organized by the European Thyroid Association. *Eur J Endocrinol* 139:584–586
- Massart C, Orgiazzi J, Maugendre D 2001 Clinical validity of a commercial method for detection of TSH-receptor binding antibodies in sera from patients with Graves' disease treated with antithyroid drugs. *Clin Chim Acta* 304:39–47
- Weetman AP 2000 Graves' disease. *N Engl J Med* 343:1236–1248
- Ranzini AC, Ananth CV, Smulian JC, Kung M, Limbachia A, Vintzileos AM 2001 Ultrasonography of the foetal thyroid: normograms based on biparietal diameter and gestational age. *J Ultrasound Med* 20:613–617
- Luton D, Fried D, Sibony O, Vuillard E, Tebeke B, Boissinot C, Leger J, Polak M, Oury JF, Blot P 1997 Assessment of fetal thyroid function by colored Doppler echography. *Fetal Diagn Ther* 12:24–27
- Goldstein I, Lockwood C, Belanger K, Hobbins J 1988 Ultrasonographic assessment of gestational age with the distal femoral and proximal tibial ossification centers in the third trimester. *Am J Obstet Gynecol* 158:127–130
- Carbone B, Fournet P, Montuclard B 1995 Rythme cardiaque fetal. In: Papiernik E, Cabrol D, Pons JC, eds. *Obstétrique*. Vol 23. Paris: Médecine Science Flammarion; 219–226
- Guibourdenche J, Noel M, Chevenne D, Vuillard E, Volumenie JL, Polak M, Bossinot C, Porquet D, Luton D 2001 Biochemical investigation of foetal and neonatal thyroid function using the ACS-180SE analyser: clinical application. *Ann Clin Biochem* 38:520–526
- Clavel S, Madec AM, Bornet H, Deviller P, Stefanutti A, Orgiazzi J 1990 Anti-TSH receptor antibodies in pregnant patients with autoimmune thyroid disorder. *Br J Obstet Gynecol* 97:1003–1008
- Daffos F, Capella-Pavlovsky M, Forestier F 1985 Fetal blood sampling during pregnancy with use of a needle guided by ultrasound: a study of 606 consecutive cases. *Am J Obstet Gynecol* 153:655–656
- Ueda D, Mitamura R, Suzuki N, Yano K, Okuno A 1992 Sonographic imaging of the thyroid gland in congenital hypothyroidism. *Pediatr Radiol* 22:102–105
- Mortimer RH, Cannell GR, Addison RS, Johnson LP, Roberts MS, Bernus I 1997 Methimazole and propylthiouracil equally cross the perfused human term placental lobule. *J Clin Endocrinol Metab* 82:3099–3102
- Johnsson E, Larsson G, Ljunggren M 1997 Severe malformations in infant born to hyperthyroid woman on methimazole. *Lancet* 350:1520
- Foulds N, Walpole I, Elmslie F, Mansour S 2005 Carbimazole embryopathy: an emerging phenotype. *Am J Med Genet* 132:130–135
- Mortimer RH, Tyack SA, Galligan JP, Perry-Keene DA, Tan YM 1990 Graves' disease in pregnancy: TSH receptor binding inhibiting immunoglobulins and maternal and neonatal thyroid function. *Clin Endocrinol (Oxf)* 32:141–152
- Cheron RG, Kaplan MM, Larsen PR, Selenkow HA, Crigler JF 1981 Neonatal thyroid function after propylthiouracil therapy for maternal Graves' disease. *N Engl J Med* 304:525–528
- Nachum Z, Rakover Y, Weiner E, Shalev E 2003 Graves' disease in pregnancy: prospective evaluation of a selective invasive treatment protocol. *Am J Obstet Gynecol* 189:159–165
- Kilpatrick S 2003 Umbilical blood sampling in women with thyroid disease in pregnancy: is it necessary? *Am J Obstet Gynecol* 189:1–2 (Editorial)
- Cohen O, Pinhas-Hamiel O, Sivan E, Dolitski M, Lipitz S, Achiron R 2003 Serial in utero ultrasonographic measurements of the fetal thyroid: a new complementary tool in the management of maternal hyperthyroidism in pregnancy. *Prenat Diagn* 23:740–742
- Skuzza KA, Sills IN, Stene M, Rapaport R 1996 Prediction of neonatal hyperthyroidism in infants born to mothers with Graves' disease. *J Pediatr* 128:264–267

JCEM is published monthly by The Endocrine Society (<http://www.endo-society.org>), the foremost professional society serving the endocrine community.